

Orthokeratology: An Update

Eef van der Worp¹ BOptom FAAO FIACLE and David Ruston² BSc FCOptom DipCLP FAAO

¹ School of Optometry, Utrecht, and Academic Hospital of the University of Maastricht, Maastricht, the Netherlands

² Johnson and Johnson Vision Care, Bracknell, Berkshire, UK

Accepted for publication 7 December 2005

Introduction

Overnight orthokeratology, corneal reshaping or vision-shaping treatment (usually generically referred to as simply orthokeratology) all refer to the technique that utilises reverse-geometry rigid contact lenses to change the shape of the cornea. This is a temporary, reversible technique. Currently it is most commonly used to flatten the central corneal curvature temporarily and reduce the corneal eccentricity and with it the patient's myopia and with-the-rule astigmatism. In this article the current status of orthokeratology worldwide will be reviewed and the possibilities, benefits and risks analysed. What is the future of orthokeratology and will it reshape our future contact lens practice?

Orthokeratology may be defined as 'a temporary reduction in myopia by the programmed application of rigid contact lenses' (Dave & Ruston 1998). By slowly flattening lens fitting by either increasing the radius of curvature of the central base curve, as described first by Jessen (1962) and later by Grant and May (1970), or by reducing the optic zone diameter (Coon 1984), a reduction in myopia and improvement of unaided vision could be made (Binder *et al.* 1980).

The evaluations made by Kerns (1976) and Polse *et al.* (1983) found that, when compared with conventional rigid gas-permeable (RGP) lens fitting, orthokeratology had, on average, little further beneficial effect in terms of myopia reduction. The average improvement in each study was a reduction in myopia of -0.75D to -1.00D . However, the procedure was shown to be safe. Interestingly, five of the 31 subjects in the study by Polse *et al.* showed a reduction in myopia of 2.00D or more, leading these authors to state that, if the corneal response variations could be better understood and controlled, then the technique could be of significance clinically.

The introduction of reverse-geometry lenses as a result of collaboration between Wlodyga and Stoyan (Wlodyga & Harris 1993) in North America led to a dramatic and rapid reduction of myopia and represented a major advance in

the technique. This time the average reduction in myopia was 2.75D over 4 months (Harris & Stoyan 1992). Hence the term 'accelerated orthokeratology' is frequently used for modern orthokeratology. These lenses still have a flat central fitting, but the steeper secondary curve is designed to prevent the decentration that would otherwise occur with flat lenses.

Further refinements in accelerated orthokeratology practice followed. Mountford (1997), for instance, introduced a fitting philosophy based on the sagittal height of the cornea. In addition to that, so-called night therapy is now practised in many developed countries. Here the lenses are worn whilst sleeping and the desired outcome is that no visual correction is required during all waking hours. Both this and daytime orthokeratology treatment using reverse-geometry lenses now have US Food and Drug Administration (FDA) approval.

The interest amongst practitioners in the procedure differs around the world. Perhaps the European country where it has been most utilised is the Netherlands (the modality was introduced about 3 years ago and it is estimated that there are more than 10 000 orthokeratology lens wearers in the Netherlands today), followed by Switzerland (Jacobsen 2005).

In summary, the essentials of accelerated orthokeratology are the reduction of myopia by the application of appropriately fitted reverse-geometry gas-permeable lenses, which reduce the corneal eccentricity and flatten the apical radius of the cornea. The maximum realistic changes that are possible using contemporary designs range between -0.75D and 4.00D of myopia and 1.50D of with-the-rule astigmatism, but new designs are on the way, especially focusing on expanding the possibilities to correct hyperopia and higher amounts of corneal astigmatism.

Mechanisms Behind Orthokeratology

The effect of overnight orthokeratology on the cornea has been the subject of intensive research in the last couple of

years. There is no doubt that modification of the anterior surface of the cornea is occurring during orthokeratology: the question is, what layers are involved and what mechanism is causing this? The response of all layers of the cornea will be reviewed separately.

Epithelium

The question when it comes to the epithelial changes is: which part of the epithelial layer is altered in what way and what is causing the change? Swarbrick *et al.* (1998) looked at the epithelial thickness, both centrally and peripherally, in 11 eyes (six subjects). They were fitted with the original Contex reverse-geometry lens for daytime wear and followed for 1 month. There was an average reduction in myopia of $1.71 \pm 0.59D$ during that time. The data for epithelial thickness showed an average thinning centrally of $8\mu m$. This was only statistically significant by day 28. There was epithelial thickening recorded in the periphery but the changes were not statistically significant due to the inherent variability in the data. The overall corneal thickness was shown to increase in the periphery, perhaps indicating that it is the epithelium that is thinning centrally and thickening peripherally. Central epithelial thinning has since been confirmed in clinical studies of overnight orthokeratology (Alharbi & Swarbrick 2003, Haque *et al.* 2004, Nichols *et al.* 2000, Soni *et al.* 2003).

The relationship between the potential refractive change in orthokeratology and the diameter of the flattened corneal surface is confirmed by the application of Munnely's formula to the situation in a similar manner to its use in Excimer laser refractive surgery. The assumption is made that orthokeratology represents an epithelial change in which there is tissue compression centrally and expansion in the mid-periphery. It has been postulated by Caroline (2000) that if the maximal amount of tissue thinning is $20\mu m$ (this hypothesis assumes that only the central epithelium is thinning) and the minimum-sized zone of flattening is 3.5mm, then the maximal predicted refractive change is $-4.40D$. This seems to correlate very well with the clinical experience of practitioners.

Choo and Caroline (2004) were able to visualise the epithelial cell changes during orthokeratology. In myopic treatment they found a decrease in the epithelial cell layers centrally and an increase in cell layers mid-peripherally in cat's eyes. For hyperopic orthokeratology they found the reversed effect (reduction in the mid-periphery, an increase centrally). This suggests a redistribution of epithelial cells as the main orthokeratology effect, although the exact relevance of changes in the cat cornea to the human situation remains currently unclear (Matsubara *et al.* 2004).

Jayakumar & Swarbrick (2005) recently confirmed this short-term epithelial response in orthokeratology, but they also found that this is age-dependent: comparing participants from 5 to 16 years of age with a group of 17–35 years and a group of 36 years and older, they found statistically significantly less epithelial change in the highest age group.

So there seems to be little doubt that there is epithelial change during orthokeratology, but the exact nature of the epithelial change is still unknown. The two most popular theories are redistribution of epithelial tissue or compression of it. According to the authors, it seems unlikely that epithelial cells have the ability to loosen their tight bonds with other cells and to move around on the corneal surface, especially since the corneal changes seem to happen very soon after lens insertion. Studies at the University of New South Wales in Australia (Sridharan & Swarbrick 2003) showed significant corneal flattening ($0.61 \pm 0.35D$; $P = 0.014$) within 10 min of lens wear. It seems hard to believe that epithelial cells are able to redistribute within such a short time, and the short-term effect most probably has a compression component to it. After that, possibly redistribution of epithelial cells takes place or possibly hyperplasia of epithelial cells in the mid-periphery with a reduction of cell renewal in the central part.

Stroma

Recently more attention has been given to the potential stromal changes in orthokeratology, in addition to the epithelial changes. Stromal changes have been proven to occur by independent investigators, but probably not over the entire ocular surface. Swarbrick *et al.* (1998) were the first to report mid-peripheral corneal thickening in orthokeratology. This mid-peripheral thickening appears to be located outside the central flattened treatment zone, under the area of the reverse curve. Research by Alharbi & Swarbrick (2003) suggests that the stromal changes occur in the mid-periphery of the cornea. The total change that takes place in the central part of the cornea is exactly matched by the epithelial change they measured, without any stromal involvement. However, in the mid-periphery the stromal change fully explains the total corneal change, while there is no significant epithelial involvement.

Choo *et al.* (2004) came to the same conclusion after fitting a cat with one orthokeratology lens for myopia and one for hyperopia. The central stroma of the myopic corrected eye was $756\mu m$ and had an average mid-peripheral stromal thickness of $805\mu m$. In the hyperopia corrected eye the central corneal thickness was $929\mu m$, with an average mid-peripheral thickness of $768\mu m$.

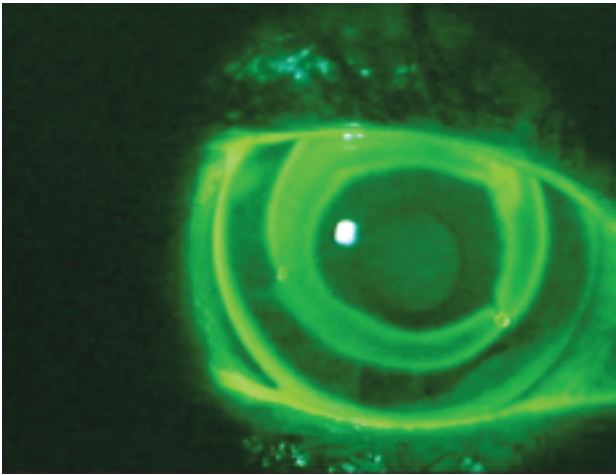


Figure 1. Lens binding and the lack of fluorescein spreading in the central and mid-peripheral zone of the orthokeratology lens.

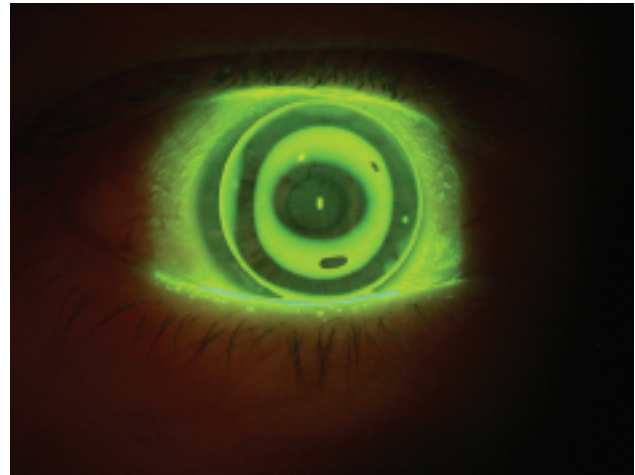


Figure 2. Toric orthokeratology lens on a cornea exhibiting with-the-rule corneal astigmatism. (Courtesy of Michael Baertschi, Switzerland.)

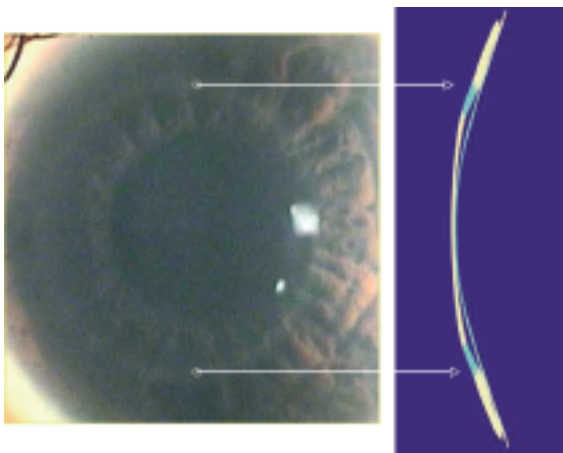


Figure 3. Ring of corneal oedema corresponding to the reverse curve of the orthokeratology lens. (Courtesy of Marco van Beusekom, Visser Contactlenzen, the Netherlands.)

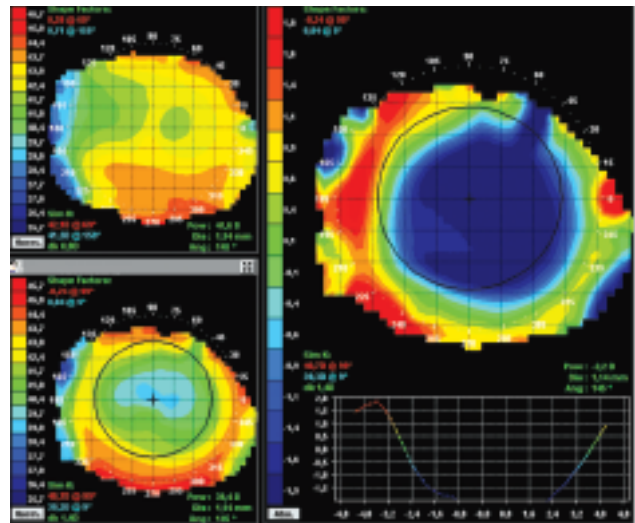


Figure 4. A bull's-eye pattern is seen in the difference map (right), which is a representation of the difference between the initial corneal topography data (top left) and the newly created corneal topography map after orthokeratology treatment (bottom left).

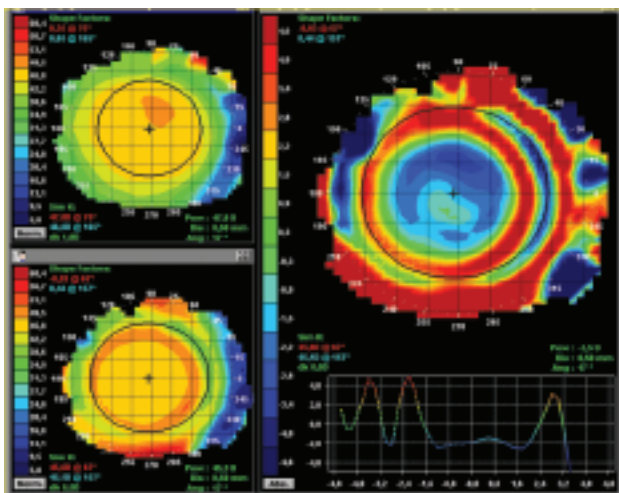


Figure 5. An apparent central island pattern is seen in the difference map (right), but this will probably resolve over time into a bull's-eye pattern.

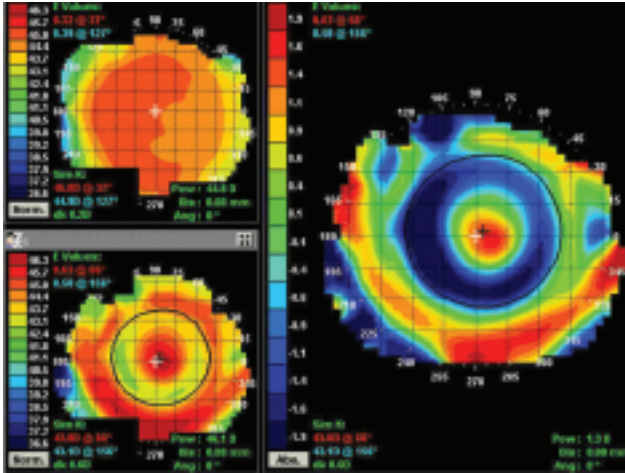


Figure 6. True central island pattern is seen in the difference map (right).

However, this was after 14 days of continuous lens wear in a closed-eye situation, which does not resemble the clinical situation in normal orthokeratology lens wear.

Alharbi *et al.* (2005) also looked at the overnight stromal response to orthokeratology lenses, and compared this to the response of normal RGP lenses with similar Dk/t values. Interestingly, they found that the central corneal stroma swelled significantly less in orthokeratology than in normal RGP lens wear, and even less than in a control group not wearing lenses at all. Similar swelling responses for the mid-periphery (3mm) and periphery (5mm) were found between the two lens groups. They explained this by suggesting that the central pressure exerted by the flat-fitting base curve of the orthokeratology lens acts locally as a ‘clamp’ to inhibit overnight central corneal swelling. Adaptation to the overnight corneal oedema occurred, which is a similar response as is seen in continuous overnight wear of conventional RGP lenses.

Matsubara *et al.* (2004) looked at corneal physiology in the corneal stroma and found that proteoglycans in the deep stroma are slightly increased centrally. They concluded that these are mild functional and morphological changes, and the significance seems limited.

A study from Manchester by Perez-Gomez *et al.* (2003) looked at the stromal keratocyte changes after cessation of orthokeratology lens wear. They found an increase in anterior stromal keratocyte density after cessation of lens

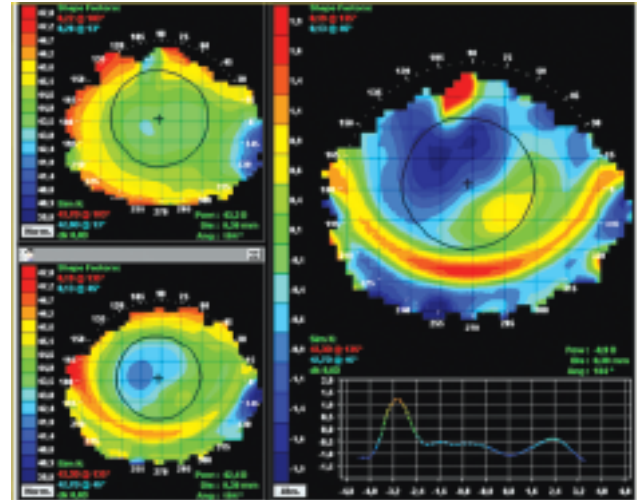


Figure 7. A smiley-face pattern is seen in the difference map (right).

wear, possibly representing a recovery from the effects of orthokeratology lens wear. Unfortunately, no data on the pre-lens wear density are available. Wang *et al.* (2004) did not find any anterior stromal changes, but the middle/posterior stromal keratocyte density gradually increased in the central region and peaked at 3 months, while the peripheral posterior numbers decreased up to 6 months. The clinical significance of the potential keratocyte changes remains unclear, especially since similar effects have been found in normal lens wear (Efron *et al.* 2002).

Bowman’s layer has not received much attention with regard to orthokeratology treatment: Bischoff (2003) from Germany studied this layer with a confocal microscope, but could not find any significant changes.

Endothelium

The focus when trying to explain the orthokeratology effect has been primarily on the anterior corneal changes, but potentially there could also be some physiological effect on the posterior layers, especially since normal contact lens wear has been shown to affect the endothelial layer. The research so far regarding the endothelial layer and Descemet’s layer did not show any significant changes. For instance, Lin (2004) found no endothelial cell density changes or morphological changes over a 6-month period using high- Dk/t lenses in overnight orthokeratology.

A potential overall bending of the cornea (including the most posterior layers) in orthokeratology based on the results above seems unlikely. However, recent work of Owens *et al.* (2004) suggested there might be some corneal bending involved in orthokeratology. Their work, in which they measured the posterior and anterior corneal change during the initial month of overnight orthokeratology, indicated some level of overall bending. They concluded that a combination of oedema and moulding is likely to account for these posterior corneal changes. Another study (Joslin *et al.* 2003) looked at corneal aberrations in orthokeratology lens wearers and also suggested overall bending. In this study they found more higher-order aberrations (specifically spherical aberration) due to the reshaping of the anterior surface, as with laser refractive surgery, which was not a surprise. However, they also found that orthokeratology increased internal optical aberrations. According to the investigators this indicates that there has to be some kind of posterior flattening in orthokeratology that is responsible for creating these internal changes.

In summary, although the mechanism behind orthokeratology is not entirely clear, epithelial changes and some stromal involvement (in the mid-periphery) seem most likely at this point to be responsible for the refractive change. Overall bending seems unlikely, although this has gained some recent attention and cannot be ruled out completely.

Safety

Whatever the mechanism of orthokeratology might be, it can be said with certainty that orthokeratology is efficacious in terms of providing a temporary reduction in myopia. The overriding concern that remains is: how safe is it? To evaluate safety, hypoxia (bacterial binding), corneal staining and corneal iron rings will be discussed.

Under hypoxic conditions, binding of bacteria to the corneal epithelium is more likely to occur (Cavanagh *et al.* 2002). This binding is potentially an increased risk factor for corneal infection. Under closed-eye conditions, as is the case in overnight orthokeratology, the oxygen tension is reduced by two-thirds from 21% in the open-eye situation (at sea level) to 7% with the eyelids closed. However, hyper-*Dk/t* RGP lens materials have been shown to supply enough oxygen to the cornea in night-and-day lens wear not to compromise corneal health in terms of increasing bacterial binding to epithelial cells (Ladage *et al.* 2001, Ren *et al.* 2002). In addition, the eye in orthokeratology is exposed to the full oxygen tension during the course of the day, which is potentially a major advantage compared to continuous

night-and-day wear of a soft or RGP lens. The term 'overnight wear' describes this new lens wear modality.

So theoretically, when orthokeratology lenses are made with the right materials, they should be relatively safe. But still, cases of corneal infections have been reported in the international literature. The known number of officially reported cases in the western world is currently 10: four in the USA, two each in Canada and in Australia plus one in the UK and one in the Netherlands (Watt & Swarbrick 2005). Additional cases have been reported ($n = 40$) in Asian countries, but the circumstances in terms of hygiene, training, equipment (no topographer, no slit lamp) and lens material (reports of polymethyl methacrylate (PMMA) use) are questioned. In addition, the amount of lens fits in Asia remains unknown, but it is estimated (Jacobson 2005) that more than 150 000 patients are wearing this modality in the region (many more had been fitted in the past, but have discontinued use). A possible risk factor for corneal infections in orthokeratology could be age: 61% of all cases around the world are in the 6–15-years age group (Watt & Swarbrick 2005). However, final conclusions in this regard cannot be drawn based on these numbers, because the amount of patients in that young age group could be very high (firm numbers are not available). Another risk factor could be Asian ethnicity: 88% of all cases around the world are of Asian ethnicity, but again, no final conclusions can be drawn from this, since the amount of fittings in this group seems exceptionally large as well.

It is currently impossible to calculate the incidence of corneal infections in orthokeratology because of the limited amount of orthokeratology lens wearers around the world and the lack of accurate data. If we look at isolated areas like North America, the ratio of known corneal infections in orthokeratology lens wearers is 1.4 in 10000. Although it should be noted that all patients wearing lenses during the night are thought to be at higher risk for corneal infections compared to daily wear, these preliminary figures seem to suggest that these values do not exceed the values for continuous lens wear with hydrogel contact lenses, and are at this point not higher than daily-wear hydrogel lens wear (Cheng *et al.* 1999).

One of the potential risk factors for corneal infection is corneal staining, which should be avoided as far as possible, although complete absence of corneal staining in lens wear, including orthokeratology, is rarely achievable. Any corneal staining should not exceed grade 1 (Cornea and Contact Lens Research Unit (CCLRU)/Efron grading scale), and it should be noted whether the staining disappears during the course of the day. However, to put corneal staining in orthokeratology into perspective, one should be aware of the fact that one of the main causes of

corneal staining in conventional RGP lens wear (3 and 9 o'clock staining) is not present in overnight orthokeratology.

Chronic lens binding can cause severe corneal staining and attempts should be made to prevent this (Figure 1): patients should be informed how to recognise when their lenses are bound and taught how to get them moving again safely. Also, extra care should be taken towards the contact lens solutions used: exposure to the preservatives is increased in orthokeratology since immediately after lens insertion the eyelid is closed in this modality.

This raises another concern regarding safety and infection risk: if a contaminated lens is placed into the eye immediately before eye closure, then the contaminating organisms can proliferate in the closed-eye environment. To prevent this as far as possible, lens care is of the utmost importance (Walline *et al.* 2005). Debris build-up should be minimised since microorganisms can attach to this surface and thus increase the risk of corneal infection. Apart from that, debris build-up could have a significant effect on the refractive outcome if the debris is located on the back surface of the lens. Additionally care of the lens case should not be overlooked (regular cleaning, air drying and regular replacement). The use of tap water in orthokeratology should be strongly discouraged since *Acanthamoeba* infections have been reported in orthokeratology wearers (Watt & Swarbrick 2005), and the organism is known to reside in tap water.

Corneal iron rings have been reported in cases of pterygium, filtering blebs, foreign bodies, laser-assisted in-situ keratomileusis (LASIK), photorefractive keratectomy, intracorneal rings, keratoplasty, keratoconus and also in orthokeratology. In orthokeratology the ring is located close to the area where the reverse curve rests on the cornea. Occurrence of iron rings may be related to the degree of reshaping. Cho *et al.* (2002a) and Barr *et al.* (2003) have reported some cases of corneal rings in orthokeratology, but apart from the presence of the rings bilaterally, the corneal integrity and topography were stable and clinically unremarkable. They concluded that, although this is an interesting finding, it does not affect visual acuity or appears to be adverse in nature and they do not progress. Cheung and Cho (2004) reported the presence of fine, white, concentric fibrillary lines in one patient undergoing orthokeratology similar to those observed in the keratoconic cornea. They speculated that both the pigmented arc and the fibrillary lines in orthokeratology may be caused by the force exerted on the cornea by the lenses.

Lens Fitting

Patient selection

Patient selection is an extremely important part of the fitting exam. Finding the right patient for this procedure decreases the chance of disappointment and also decreases the risk of adverse events, and it builds confidence on the part of the practitioner and the patients. The suitability of patients for orthokeratology depends on many variables, which can be reduced to four categories: (1) the amount of ametropia; (2) pupil size; (3) current contact lens wear; and (4) anatomical/physiological and pathological considerations of the eye.

Ametropia

Although the US FDA has approved orthokeratology for myopia up to $-6.00D$, mild to moderate myopia ($-0.75D$ to $-4.00D$) has proved to be most successful. The amount of myopia that can be treated is dependent on many variables, of which pupil size is one of the most prominent. Also, the amount of flattening (eccentricity) towards the periphery of the cornea, as suggested by Mountford (1997), is thought to be of importance (higher eccentricity can enable higher amounts of myopia to be corrected), although this is still under debate. To be on the safe side, and especially if the practitioner is not an experienced orthokeratology lens fitter, it is advisable, based on the available literature and clinical experience, not to guarantee the success of the therapy beyond $-4.00D$.

Correction of hyperopia has gained less attention with orthokeratology lenses so far. However, recent studies have shown that correction of hyperopia is feasible (Sorbara 2005, Swarbrick *et al.* 2004) but due to a limited optical zone diameter it will probably be restricted to the lower amounts of hyperopia. According to Swarbrick *et al.* (1999), the corneal steepening response may be slower in onset than the flattening response in myopia. Studies with enhanced back-surface geometries for hyperopia are currently under way. Also, the possibility of creating aspheric corneas to correct presbyopia are under investigation, but again the limited size of the created optical zone will most probably limit the outcome. For presbyopes, monovision is available as a correction option. In the authors' opinion, it is advisable to correct both eyes for distance first, to evaluate the outcome, and from there to decide which eye performs best for far: the other eye can be used for near vision.

Correction of astigmatism has been one of the major limitations in today's orthokeratology practice. First of all,

with standard orthokeratology lenses only corneal astigmatism can be corrected (residual refractive astigmatism due to internal astigmatism can possibly complicate the refractive outcome). The main rule of thumb is that about 50% (Mountford & Pesudovs 2002) of central, with-the-rule corneal astigmatism can be corrected with standard orthokeratology lenses. This means there are several limitations to the correction of astigmatism: with-the-rule corneal astigmatism only, and in addition it should be located centrally on the cornea since limbal-to-limbal corneal astigmatism is much more challenging to correct. All in all, only candidates with about 1.50D of central, corneal and with-the-rule astigmatism are likely to achieve acceptable levels of uncorrected vision with the current standard lens designs.

However, toric orthokeratology lenses are currently being developed and evaluated, with success. A large study in Switzerland (Baertschi 2005) showed that 82.5% of toric orthokeratology lenses fitted in this study were successful; the researchers also showed that inexperienced orthokeratology lens fitters (who had completed fewer than 10 standard orthokeratology lens fits) were as successful in fitting them as experienced lens fitters (Figure 2). Another study in the Netherlands (Beerten *et al.* 2005) independently reached similar conclusions: toric orthokeratology lenses can be fitted successfully for with-the-rule astigmatism up to 3.50D, and even correction of against-the-rule corneal astigmatism might be possible. In this study, 70% of patients achieved an unaided visual acuity of 6/9 in both eyes.

Pupil size

It is well known that orthokeratology – as well as surgical procedures such as LASIK – induce higher-order aberrations, especially spherical aberration. For large pupil sizes, the amount of higher-order aberrations increases dramatically. Therefore it is important to be precise about pupil size, and/or the size of the optical zone. From a clinical standpoint, an optical zone diameter of 4–5mm usually appears to be adequate to satisfy patients with normal pupil diameter (6mm under dim light conditions). The pupil size can be measured using a handheld ruler, the slit lamp with a ruler or using the topographer.

However, all of these techniques are influenced by the light conditions that are necessary to make the measurement. Infrared pupil meters are much better in predicting the size of the pupil under dim light conditions. Many different pupil meters are available (most are used for refractive surgery purposes), but in addition to these, autorefractor

equipment and non-mydriatic fundus cameras also use infrared and might be useful to give the practitioner an indication of the pupil size under dim light conditions. In addition, from a clinical standpoint it is suggested that patients with deeper anterior chamber depths use a larger surface of the corneal optics, and consequently they may require slightly larger optical zone diameters.

In addition to optical zone size in relation to pupil size, lens centration (and thus treatment zone centration) will interact with pupil size in terms of subjective visual performance. So not only must the treatment zone be large enough to accommodate the pupil, but it should also be centred on the pupil. Corneal topography (and in particular the tangential map: see section on topography, below) will provide the practitioner with information about this.

Current contact lens wear

Alterations of the corneal topography during contact lens wear have been reported by many researchers (Maeda *et al.* 1994, Ruiz-Montenegro *et al.* 1993, Wilson *et al.* 1990a). The resting position of the lens on the cornea seems to play an important role; the topography of warped corneas is usually characterised by a relative flattening of the cornea underlying the RGP contact lens in its resting position. Lenses that ride high, for example, produce flattening superiorly and result in a relatively steeper contour inferiorly (Wilson *et al.* 1990b).

Recently, the impact of contact lenses on the cornea has become increasingly apparent within the framework of laser refractive surgery (Budak *et al.* 1999, Wang *et al.* 2004). RGP lens wearers frequently need to cease lens wear for many weeks before surgery so that the cornea can return to its baseline shape. One refractive surgery centre in the Netherlands reported that 95% of all retreatments for refractive reasons were performed on previous RGP lens wearers (R Lafeber 2004, personal communication).

This is also of importance when fitting orthokeratology lenses: the cornea needs to be in a steady state before these lenses can be fitted. The amount of time to cease lens wear is still under debate. For RGP lenses a general period of 3–4 weeks is suggested by Mountford *et al.* (2004) before the cornea returns to its original state, but more for long-term RGP lens wearers and also more for patients wearing low-*Dk* lens materials. For PMMA lens wearers, refitting with standard RGP lenses and then gradually ceasing lens wear seems to be the preferred method. Also practitioners should be aware that back aspheric bifocal lenses tend to alter the shape of the cornea to a greater extent.

Furthermore, care must be taken with regard to hydrogel wearers since the cornea might be altered or even warped with these lenses. It is advised to cease lens wear for at least 3–4 days with hydrogels, but again much longer periods might be needed if thick low-*Dk* materials are worn. Both existing hydrogel and RGP lens wearers are best avoided in the beginning if the practitioner is not an experienced orthokeratology lens fitter. To be on the safe side in avoiding corneal warpage, it may even be advisable to follow the guidelines that apply for refractive surgery, such as to cease lens wear for 8 weeks in the case of RGP lenses and at least 2 weeks for hydrogel lenses, followed by corneal mapping at 2-week intervals until the topography is stable (0.50D change or less compared to the last visit).

Anatomical/physiological and pathological considerations

Deep-set eyes and loose eyelids as well as lower than normal upper eyelids and narrow apertures are all mentioned as potential anatomical limitations of orthokeratology. This is mostly due to an increased difficulty in making an accurate and extensive topography map, and also due to an increased risk of decentration of the lens, which is considered a major obstacle when it comes to successful orthokeratology fitting. However, all of these are considered to be relative contraindications.

When it comes to potential physiological limitations, hypoxia is one that should be considered, since overnight lens wear always challenges the cornea more than daily wear. Although it is extremely rare to see any signs of hypoxia in orthokeratology, Figure 3 represents an exception to that rule: a ring of corneal oedema corresponding with the reverse zone is visible. In addition to this, recent studies indicate that stromal oedema induced by low-*Dk/t* lenses plays a role in the clinical outcome of the procedure, and the high-*Dk* materials should be used at all times in overnight orthokeratology. Apart from that, frequent replacement systems (lens replacement annually is advised) and intensive cleaning systems should be used to prevent build-up of debris on the lens.

With regard to the age of the wearer in orthokeratology, more infections have been found in children than in older wearers, but it is not clear if this is indeed an extra risk factor since the numbers of lens fits in children worldwide is large as well (see discussion above). Paying extra attention to following consistent aftercare protocols with children and their parents with this modality seems wise. Although young individuals tend to have larger pupils – a perceived disadvantage when it comes to orthokeratology – this hardly ever seems to be a problem in everyday

practice. This probably has to do with the fact that children generally do not have high visual requirements when playing or drive at night. Older corneas might have their limitations as well: a reduced response to orthokeratology has been found in older compared to younger age groups (Jayakumar & Swarbrick 2005). Although this could be taken into consideration during lens fits, it is not considered a contraindication for orthokeratology.

Dry eyes also need to be approached with care in orthokeratology lens fitting. The consequences largely depend on the severity of the condition. For marginal dry eyes there are a couple of potential difficulties. First of all, it might be a challenge to create a reliable topography map, since corneal topographers need a good wettable corneal surface: dry spots will lead to errors. Also, excessive meibomian gland secretion can lead to substantial alterations of the topography map (Markomanolakis *et al.* 2005), so it is advisable always to take care of meibomian gland dysfunction first. Furthermore, because of the altered tear film composition in dry eyes, more debris build-up might be seen, leading to the problems described earlier. However, a lot of patients with dry-eye problems while wearing their existing hydrogel lenses are being refitted with great success with orthokeratology. In addition the RGP lens complication of 3 and 9 o'clock staining simply does not occur in overnight orthokeratology. In other words, for patients with signs of dry eyes while wearing their existing lenses, orthokeratology can be successful, but a true dry eye is an absolute contraindication.

Other true contraindications for orthokeratology include all corneal dystrophies, corneal degenerations and anterior-segment disease (especially herpes simplex, adenovirus and anterior uveitis). Special care should be taken to diagnose corneal ectasia such as keratoconus and pellucid marginal degeneration before starting with orthokeratology: these are also considered absolute contraindications.

Lens designs

The basics of the lens design features can be divided into three components. First is the central (optical) zone. The shape of this zone reflects the refractive power change that is intended, regardless of the technique that is used to calculate it. From a practical standpoint, this means that patients are always able to see clearly with the lens on the eye: during the adaptation phase, during the night and sometimes simply when excellent vision is required (driving at night, for instance). A typical optic zone size of the lens is 6.00mm.

The second curve to consider is the peripheral curve or alignment curve. This curve represents the fitting curve and is responsible for centration of the lens, which is crucial in orthokeratology. It should be fitted in alignment with the slope of the peripheral cornea. The peripheral curves can be spherical or aspherical, or – as in some of the modern orthokeratology lens designs – a variable tangent to align the lens with the peripheral cornea. Tangents are straight lines, not curves. Changing either the alignment configuration or the tangent angle alters the sagittal height of the lens.

With orthokeratology, the aim is always to create a thin tear layer over the apex of the cornea. If the exact sagittal height of the cornea were known, this would be an easy task. Unfortunately, corneal topographers are not able to give an exact estimate of corneal height. They will over- or underestimate the sagittal height and practitioners should manually correct this based on fluorescein pattern evaluation and post-treatment topography data. Some topographers are better able to produce reliable and reproducible data (Cho *et al.* 2002b) than others. Several corneal topography measurements should be performed to eliminate potential erroneous measurements by providing an average figure.

The third zone to be established is the reverse zone, and the major difference in design between most available lenses on the market today regards this zone. The reverse zone connects the (fixed) optical zone with the alignment curve. The complexity of the reverse curve zone structure leads to the three-, four- and five-zone orthokeratology lenses that are currently available.

Various designs are available from a number of sources. However, when several popular modern overnight reverse-geometry lenses were compared (Tahhan *et al.* 2003), no dramatic differences in outcomes were noted. The study comparing the Contex, Driemlens, BE and Reinhart & Reeves designs found that the subjective rating and unaided visual acuity were not significantly different. The only slight difference that was found related to the treatment zone diameter: the BE lens showed a slightly larger treatment zone diameter.

One potential way of evaluating the accuracy of the fit and the desired effect is to look at the fluorescein pattern. For an ideal lens fit, there should be an apparent area of central touch 3–4mm wide, surrounded by a wide annulus of fluorescein about 60µm deep which forms the tear reservoir. This is then surrounded by a band of peripheral touch that supports the lens. This is about 0.75mm wide and should taper in from the tear reservoir out to the edge. Finally, there is an edge band of fluorescein showing the

same degree of edge clearance as a conventional lens (60–70µm). Tears should be seen to flow through any fenestrations if present. Further requirements for a successful orthokeratology lens fit is that it should move 1.0–1.5mm on blinking and that it must centre perfectly: the latter is the key to a good distortion-free orthokeratology result.

Evaluation of lens fit with fluorescein has been used ever since rigid lenses came on to the market. It has been proven to be highly useful in clinical practice, although the human eye is only able to detect fluorescein layers that are about 20µm or thicker (Carney *et al.* 1997, Guillon & Sammons 1994). This means that everything thinner than 20µm appears dark. Because of this it is extremely difficult to fit orthokeratology lenses based on fluorescein evaluation alone, for both inexperienced orthokeratology lens fitters as well as experienced orthokeratology lens fitters (Mountford *et al.* 2005).

Topography

An instrument that measures the corneal topography is essential to the practice of orthokeratology. It is used for three different purposes: (1) to diagnose any irregularities of the cornea before lens fit (including keratoconus-like patterns); (2) to predict better the amount of ametropia that can be corrected based on the corneal shape and calculation of the corneal sagittal height (which will determine what initial lens is ordered); and (3) especially to follow the effect of the lens on the eye and refine the lens fit.

To evaluate the lens fit, three classical patterns can be detected if a difference map is created between the initial corneal topography and the newly created corneal topography under the orthokeratology lens. A bull's-eye pattern is the desired outcome where a central flat area is visible surrounded by a ring of relative steepening (Figure 4). The size of this central flat area tends to increase with time (the first night it does not necessarily cover the entire pupil area). The second possible pattern that occurs in orthokeratology is a central island, which is usually fairly simple to recognise: a small area of relative steep curves (lighter colours) can be seen within the optical zone of the eye. It is important to evaluate whether this area is flatter than the original curves of the central cornea. If this small island is flatter than the original cornea, it most probably will resolve in a matter of days (Figure 5). In other words, keep using the current lens and it will evolve into a bull's eye. However, if the island represents steeper curves than the original cornea, this is most probably a true central island (Figure 6). The topographer overestimated the

sagittal height of the cornea, eg the cornea is in reality 'flatter' than calculated. A new, flatter lens is needed to resolve this situation.

As a third option, a smiley-face pattern might be seen (Figure 7). In this case the lens is too flat for the cornea or, in other words, the lens sag is too low. Decentration of the lens is common, mostly superior, and the flattest area of the cornea is displaced superiorly. A partial ring representing steeper areas will be partly covering the optical zone of the cornea, leading to decreased visual acuities. The cornea is steeper here than the topographer had estimated, and a steeper lens fit with a greater sagittal height is desired.

Different topography scales can and should be used to evaluate the orthokeratology outcome (Mountford *et al.* 2004). The axial map is best used to evaluate the refractive effect, ie it corresponds best with the subjective refraction. The tangential map is essential to evaluate the centration of the lens, which is crucial in fitting orthokeratology lenses. The refractive power map estimates best the size of the treatment zone (the axial and tangential maps can over- or underestimate the effect). Care should be taken when making corneal maps: the tear film can break up, which can lead to abnormal outcomes, and also corneal staining can lead to erroneous measures. It is advisable always to take more than one picture to overcome this problem, and always check the cornea for staining prior to taking the topography map.

Quality of Vision in Orthokeratology

As mentioned before, the orthokeratology effect happens extremely fast. Statistically significant changes in corneal curvature and unaided vision have been found after just 10 min of lens wear (Sridharan & Swarbrick 2003). For a targeted refractive change of 2.00D, these authors estimated that 60% of the refractive change had occurred after 1 h of lens wear and 80% of the effect takes place after the first occasion of overnight lens wear. This raises questions about the stability of the procedure and the rebound effect during the day when no lenses are worn. However, little regression during the day has been reported. Mountford (1998) analysed whether there was any refractive change during the day for 48 patients who were in an overnight treatment program. He looked at the regression of the myopia at 7, 30 and 90 days after the initial fitting. He measured the anterior corneal power objectively using the EyeSys corneal topographer after the patients removed their lenses in the morning and then 8 h later. Mountford had a control group of nine non-lens

wearers. The latter group showed no significant change in anterior corneal power (0.04D). The orthokeratology patients showed the results detailed in Table 1.

Table 1. The change in anterior corneal power and the speed at which that change reduced over an 8-h period, ie the degree of regression (Mountford 1998)

Time of change	Anterior corneal power (D) \pm standard deviation	Regression (D) \pm standard deviation
Day 7	1.93 \pm 0.75	0.52 \pm 0.61
Day 30	2.23 \pm 0.57	0.43 \pm 0.44
Day 90	2.39 \pm 0.48	0.41 \pm 0.26

Thus, by 1 month the majority of the measured change in corneal power (and therefore reduction in myopia) has occurred and by 3 months it wears off at an average rate of 0.41D over an 8-h period. Individuals do show variations in the speed of regression, but most of the time, the variation is not very different from average. Barr *et al.* (2004) found that 90% of recovery towards baseline refractive error had occurred after 72 h of lens wear discontinuation. Similarly, Soni *et al.* (2004) reported rapid recovery of corneal thickness and curvature towards prefitting values after cessation of lens wear following 1 month of overnight orthokeratology wear.

Typically, practitioners will use high-contrast Snellen charts to measure the vision acuity after orthokeratology treatment. The study of Nichols *et al.* (2000) showed that there was a highly significant improvement in high-contrast acuity using logMAR charts. By the 30th day of their study all subjects could see the equivalent of 6/7.5 or better unaided, representing a seven-line increase in vision. There was a six-line increase in low-contrast vision. The corrected visual acuity should always be at least as good as the best corrected pre-fit visual acuity (Mountford *et al.* 2004).

Comments about poor night vision and haloes or flare effects seem to be very rare in clinical practice, according to the authors, compared to patients that underwent refractive surgery. This is surprising in view of the relatively small treatment zones produced. There is, however, no peer-reviewed published study looking into the visual quality in orthokeratology patients. It is hypothesised by the authors that the gradual transition from central to peripheral zone may, in part, be responsible for this effect.

The Future

At present modern orthokeratology techniques seem able to induce up to 4D changes in corneal power. It seems to be a relatively safe and reversible way of effecting a temporary reduction in myopia. In addition, astigmatic correction seems feasible now to some degree and new lens designs are emerging for hyperopia.

Anecdotally, many orthokeratology practitioners feel that their young patients do not experience an increase in myopia and that therefore the procedure has some form of stabilising effect on juvenile-onset myopia. Studies are under way to confirm these findings, and any cause may lie in manipulating and managing the induced higher-order aberrations in orthokeratology (Caroline 2005). These may lead to a retarding effect on the axial length growth that has been found in some children undergoing orthokeratology (Cho *et al.* 2005). But until scientific confirmation is given, the authors advise that patients be told that any evidence for an effect on myopic progression is anecdotal.

Conclusion

Accelerated orthokeratology is one of several possibilities that may be offered to the patient with moderate myopia and low with-the-rule astigmatism who seeks freedom from spectacles or conventional contact lenses. It is a minimally invasive, reversible technique that appeals to patients who are unsure whether they wish to opt for refractive surgery or who are too young for surgery to be considered. Many patients choose this technique because of contact lens-related dry-eye symptoms and other comfort-related issues with their existing lenses. However, they always need to be reminded that the effects of orthokeratology treatment are not permanent and that lens wear and care are required on a frequent basis for the effects to be sustained. If, in addition, orthokeratology proves to have an effect on myopia progression, then orthokeratology could indeed reshape the future of contact lens practice.

References

- Alharbi A, Swarbrick HA (2003) Effects of overnight orthokeratology lens wear on corneal thickness. *Invest Ophthalmol Vis Sci* **6**, 2518–23
- Alharbi A, La Hood D, Swarbrick HA (2005) Overnight orthokeratology lens wear can inhibit the central stromal edema response. *Invest Ophthalmol Vis Sci* **7**, 2334–40
- Baertschi M (2005) Short and long term success with correction of high astigmatism in OK. Paper presented at the Global Orthokeratology Symposium, Chicago, July
- Barr JT, Rah MJ, Jackson JM, Jones LA (2003) Orthokeratology and corneal refractive therapy: a review and recent findings. *Eye Contact Lens* **1** (suppl), S49–53
- Barr JT, Rah MJ, Meyers W, Legerton J (2004) Recovery of refractive error after corneal refractive therapy. *Eye Contact Lens* **30**, 247–51
- Beerten R, Christie C, Sprater N, Ludwig F (2005) Improving orthokeratology results in astigmatism. Poster presented at the Global Orthokeratology Symposium, Chicago, July
- Binder PS, May CH, Grant SC (1980) An evaluation of orthokeratology. *Ophthalmology* **87**, 729–44
- Bischoff G (2003) Microstructural corneal changes in orthokeratology. Presentation at the European Contact Lens Ophthalmologists Symposium, Venice, May
- Budak K, Hamed AM, Friedman NJ, Koch DD (1999) Preoperative screening of contact lens wearers before refractive surgery. *J Cataract Refract Surg* **25**, 1080–6
- Carney LG, Mainstone JC, Henderson BA (1997) Corneal topography and myopia. A cross-sectional study. *Invest Ophthalmol Vis Sci* **38**, 311–20
- Caroline P (2000) Address to British Contact Lens Conference, Birmingham, June
- Caroline P (2005) The myopia control data: what does it all mean? Paper presented at the Global Orthokeratology Symposium, Chicago, July
- Cavanagh D, Ladage P, Yamamoto K, Molai M, Ren D, Petroll M, Jester J (2002) Effects of daily and overnight wear of a novel hyper oxygen-transmissible soft contact lens on bacterial binding and corneal epithelium. *Ophthalmology* **11**, 1957–69
- Cheng KH, Leung SL, Hoekman HW (1999) Incidence of contact-lens-associated microbial keratitis and its related morbidity. *Lancet* **354**, 181–5
- Cheung P, Cho P (2004) Case report: fibrillary lines on the cornea of a child wearing overnight orthokeratology lenses. Poster presented at the Global Orthokeratology Symposium, Toronto, August
- Cho P, Lam AK, Mountford JA (2002a) The performance of four different corneal topographers on normal human corneas and its impact on orthokeratology lens fitting. *Optom Vis Sci* **3**, 175–83
- Cho P, Chui WS, Mountford JA, Cheung SW (2002b) Corneal iron ring associated with orthokeratology lens wear. *Optom Vis Sci* **9**, 565–8
- Cho P, Cheung SW, Edwards M (2005) The longitudinal orthokeratology research in children (LORIC) in Hong Kong: a pilot study on refractive changes and myopic control. *Curr Eye Res* **30**, 71–80
- Choo J, Caroline P (2004) Morphological changes in cat epithelium following overnight lens wear with the Paragon CRT lens for corneal reshaping. Paper presented at the Global Orthokeratology Symposium, Toronto, August
- Choo J, Caroline P, Harlin D, Meyers W (2004) Morphological changes in cat stroma following 14 days of continuous wear of Paragon CRT lenses. Paper presented at the American Academy of Optometry, San Diego, December
- Coon LJ (1984) Orthokeratology, part 2: evaluating the Tabb method. *J Am Optom Assoc* **55**, 409–18
- Dave T, Ruston DM (1998) Current trends in modern orthokeratology. *Ophthalm Physiol Opt* **18**, 224–33

- Efron N, Perez-Gomez I, Morgan PB (2002) Confocal microscopic observations of stromal keratocytes during extended contact lens wear. *Clin Exp Optom* **3**, 156–60
- Grant SC, May CH (1970) Orthokeratology – a therapeutic approach to contact lens procedures. *Contacto* **4**, 3–16
- Guillon M, Sammons W (1994) Contact lens design. In: Ruben M, Guillon M (eds) *Contact Lens Practice*, pp. 87–112. London: Chapman & Hall
- Haque S, Fonn D, Simpson T, Jones L (2004) Corneal and epithelial thickness changes after 4 weeks of overnight corneal refractive therapy lens wear, measured with optical coherence tomography. *Eye Contact Lens* **30**, 189–93
- Harris D, Stoyan N (1992) A new approach to orthokeratology. *Contact Lens Spect* **4**, 37–39
- Jacobson J (2005) Orthokeratology: the global perspective. Paper presented at the Global Orthokeratology Symposium, Chicago, July
- Jayakumar J, Swarbrick HA (2005) The effect of age on short-term orthokeratology. *Optom Vis Sci* **6**, 505–11
- Jessen GN (1962) Orthofocus technique. *Contacto* **7**, 200–4
- Joslin C, Wu S, McMahon T, Shahidi M (2003) Higher-order wavefront aberrations in corneal refractive therapy. *Optom Vis Sci* **12**, 805–11
- Kerns R (1976) Research in orthokeratology. Parts 1–8. *J Am Optom Assoc* **47**, 1047–51
- Ladage P, Yamamoto K, Ren D (2001) Effects of rigid and soft contact lens daily wear on corneal epithelium, tear lactate dehydrogenase, and bacterial binding to exfoliated epithelial cells. *Ophthalmology* **108**, 1279–88
- Lin JC (2004) The effect of orthokeratology on the morphology of the central and peripheral corneal endothelium, Paper presented at the Global Orthokeratology Symposium, Toronto, August
- Markomanolakis MM, Kymionis GD, Aslanides IM, Astyrakakis N, Pallikaris IG (2005) Induced videokeratography alterations in patients with excessive meibomian secretions. *Cornea* **24**, 16–19
- Matsubara M, Kamei Y, Takeda S, Mukai K, Ishii Y, Ito S (2004) Histologic and histochemical changes in rabbit cornea produced by an orthokeratology lens. *Eye Contact Lens* **30**, 198–204
- Maeda N, Klyce SD, Smolek MK, Thompson HW (1994) Automated keratoconus screening with corneal topography analysis. *Invest Ophthalmol Vis Sci* **35**, 2749–57
- Mountford JA (1997) An analysis of the changes in corneal shape and refractive error induced by accelerated orthokeratology. *ICLC* **24**, 128–43
- Mountford JA (1998) Retention and regression of orthokeratology with time. *ICLC* **25**, 1–6
- Mountford J, Pesudovs K (2002) An analysis of the astigmatic changes induced by accelerated orthokeratology. *Clin Exp Optom* **85**, 284–93
- Mountford JA, Ruston D, Dave T (2004) *Orthokeratology*. London: Butterworth-Heinemann
- Mountford J, Cho P, Chui WS (2005) Is fluorescein pattern analysis a valid method of assessing the accuracy of reverse geometry lenses for orthokeratology? *Clin Exp Optom* **1**, 33–8
- Nichols J, Bullimore M, Marsich M, Nguyen M, Barr J (2000) A prospective study of overnight orthokeratology. *Optom Vis Sci* **5**, 252–9
- Owens H, Garner LF, Craig JP, Gamble G (2004) Posterior corneal changes with orthokeratology. *Optom Vis Sci* **6**, 421–6
- Perez-Gomez I, Moldondo-Codina C, Efron S, Efron N (2003) Confocal evaluation of corneal changes after orthokeratology. Poster American Academy of Optometry #24, Dallas
- Polse KA, Brand RJ, Schwalbe JS (1983) The Berkley orthokeratology study. Part 2: efficacy and duration. *Am J Optom Physiol Opt* **3**, 187–198
- Ren D, Yamamoto K, Ladage P (2002) Adaptive effects of 30-night wear of hyper-O(2) transmissible contact lenses on bacterial binding and corneal epithelium: a 1-year clinical trial. *Ophthalmology* **109**, 27–40
- Ruiz-Montenegro J, Mafra CH, Wilson SE, Jumper JM, Klyce SD, Mendelson EN (1993) Corneal topographic alterations in normal contact lens wearers. *Ophthalmology* **100**, 128–34
- Soni PS, Nguyen TT, Bonanno JA (2003) Overnight orthokeratology: visual and corneal changes. *Eye Contact Lens* **29**, 137–45
- Soni PS, Nguyen TT, Bonanno JA (2004) Overnight orthokeratology: refractive and corneal recovery after discontinuation of reverse-geometry lenses. *Eye Contact Lens* **30**, 254–62
- Sorbara G (2005) Topographic keratometric effects of corneal refractive therapy for hyperopia after one night of lens wear. Paper presented at the Global Orthokeratology Symposium, Chicago, July
- Sridharan R, Swarbrick HA (2003) Corneal response to short-term orthokeratology lens wear. *Optom Vis Sci* **3**, 200–6
- Swarbrick HA, Wong G, O'Leary D (1998) Corneal response to orthokeratology. *Optom Vis Sci* **11**, 791–9
- Swarbrick HA, Katalinic P, Corti D (1999) Induction and recovery of corneal topographic changes with apical touch and apical clearance rigid contact lenses. ARVO abstract. *Invest Ophthalmol Vis Sci* **40**, S908
- Swarbrick HA, Hiew R, Kee AV, Peterson S, Tahhan N (2004) Apical clearance rigid contact lenses induce corneal steepening. *Optom Vis Sci* **6**, 427–35
- Tahhan N, Du Toit R, Papas E, Chung H, La Hood D, Holden AB (2003) Comparison of reverse-geometry lens designs for overnight orthokeratology. *Optom Vis Sci* **12**, 796–804
- Wang Q, Leach N, Giannoni AG, Parker K, Miller W (2004) The effect of orthokeratology on corneal cell densities. Paper presented at the American Academy of Optometry, San Diego, December
- Watt K, Swarbrick HA (2005) Microbial keratitis in overnight orthokeratology: review of the first 50 cases. *Eye Contact Lens* **31**, 201–8
- Walline JJ, Holden BA, Bullimore MA *et al.* (2005) The current state of corneal reshaping. *Eye Contact Lens* **31**, 209–14
- Wilson SE, Lin DT, Klyce SD, Reidy JJ, Insler MS (1990a) Topographic changes in contact lens-induced corneal warpage. *Ophthalmology* **97**, 734–44
- Wilson SE, Lin DT, Klyce SD, Reidy JJ, Insler MS (1990b) Rigid contact lens decentration: a risk factor for corneal warpage. *CLAO J* **16**, 177–82
- Wlodyga RJ, Harris D (1993) *Accelerated Orthokeratology Techniques and Procedures Manual*, part 1, pp 1–7. Chicago: National Eye Research Foundation

Multiple Choice Questions

This paper is reference C-3977. Four credits are available. Please use the inserted answer sheet. Copies can be obtained from Optometry in Practice Administration, PO Box 6, Skelmersdale, Lancashire WN8 9FW. There is only one correct answer for each question.

-
1. The mechanism of orthokeratology was first described in the early:
 - (a) 1960s
 - (b) 1970s
 - (c) 1980s
 - (d) 1990s
 2. Up to what level of myopia can usually be corrected in most patients?
 - (a) -2.00D
 - (b) -3.00D
 - (c) -4.00D
 - (d) -5.00D
 3. Which of the following is the most important fitting characteristic in terms of successful visual outcome?
 - (a) adequate movement
 - (b) adequate diameter
 - (c) adequate edge lift
 - (d) good centration
 4. The average regression after 8 hours of cessation in orthokeratology on average is:
 - (a) 0.40D
 - (b) 0.80D
 - (c) 1.20D
 - (d) 1.50D
 5. What kind of corneal astigmatism is most readily corrected with orthokeratology?
 - (a) against-the-rule corneal astigmatism
 - (b) with-the-rule astigmatism
 - (c) limbus-to-limbus corneal astigmatism
 - (d) all of the above
 6. When refitting conventional RGP wearers with orthokeratology lenses, how long should the cornea be given to normalise in shape before commencing the fitting?
 - (a) 1 day
 - (b) 1 week
 - (c) 2 weeks
 - (d) 3-4 weeks
 7. Which of the following is not typically found in overnight orthokeratology lens wearers?
 - (a) 3-9 o'clock staining
 - (b) toxic reactions to contact lens solutions
 - (c) chronic lens binding
 - (d) central staining through a flat-fitting lens
 8. What mechanism is currently most likely to cause the short-term epithelial changes in orthokeratology?
 - (a) compression
 - (b) redistribution
 - (c) neither (a) nor (b)
 - (d) both (a) and (b)
 9. When considering the changes in stromal keratocyte density during orthokeratology lens wear, these changes:
 - (a) also happen in normal contact lens wear
 - (b) are opposite to those seen in normal contact lens wear
 - (c) are not seen in normal contact lens wear
 - (d) are double those observed in normal contact lens wear
 10. Which of the following statements regarding epithelial changes in orthokeratology lens wearers is true?
 - (a) less short-term effect is seen in younger patients
 - (b) less short-term effect is seen in older patients
 - (c) no difference in epithelial change is found with regard to age
 - (d) the effect of age on the outcome is still unknown
 11. With regard to stromal changes in orthokeratology, what change seems most likely to occur?
 - (a) central thickening
 - (b) central thinning
 - (c) mid-peripheral thickening
 - (d) mid-peripheral thinning
 12. With regard to dry eyes and orthokeratology:
 - (a) dry-eye symptoms are an absolute contraindication
 - (b) pathological dry eye is not a contraindication
 - (c) dry-eye symptoms are an indication
 - (d) dry-eye symptoms are sometimes a contraindication, but can be an indication as well

13. To evaluate the centration of the orthokeratology lens fit, which corneal topography map is best used?
- (a) axial map
 - (b) tangential map
 - (c) refractive power map
 - (d) all of the above
14. A smiley face corneal topography outcome is characterised by:
- (a) a central zone of steepening
 - (b) flat-fitting relationship
 - (c) good centration
 - (d) a smaller sagittal height of the lens is desired
15. A central island topography map that is taken shortly after the initial fit will probably resolve over time (into a bull's eye) if the k -values in the centre of the island are:
- (a) flatter than the original central k -values
 - (b) steeper than the original k -values
 - (c) the same as the original k -values
 - (d) the central k -values do not make a difference
16. In North America the ratio of known corneal infections in orthokeratology wearers is approximately:
- (a) 1.4 in 100
 - (b) 1.4 in 1000
 - (c) 1.4 in 10 000
 - (d) 1.4 in 100 000
17. Which of the following patients would be most likely to achieve acceptable levels of uncorrected vision with current standard lens designs?
- (a) a -3.00 DS myope with central corneal against-the-rule astigmatism
 - (b) a -2.50 DS myope with limbal-to-limbal corneal with-the-rule astigmatism
 - (c) a -7.00 DS myope with central corneal with-the-rule astigmatism
 - (d) a -4.00 DS myope with central corneal with-the-rule astigmatism
18. Which of the following statements is false?
- (a) Orthokeratology has been shown to reduce higher-order aberrations
 - (b) Patients with deeper anterior chambers may require slightly larger optical zone diameters
 - (c) Comments about poor night vision are rare in clinical practice
 - (d) There is increased exposure to solution preservatives in orthokeratology